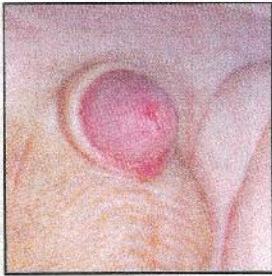

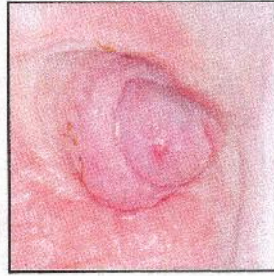# DAY 10

Most of the healing tissue have come off by now.

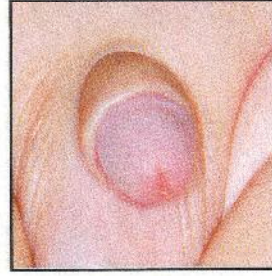
Patient A



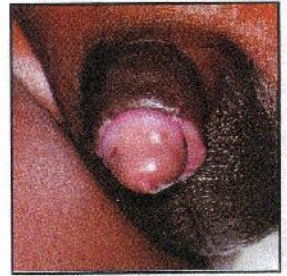Patient B



Patient C

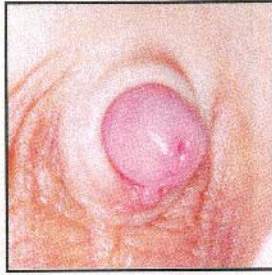

Patient D

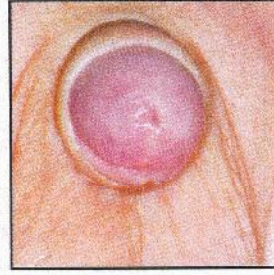

Still a bit swollen, normal

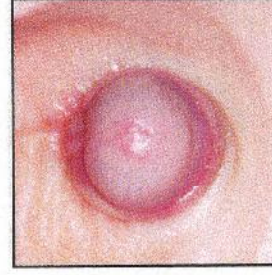Patient E



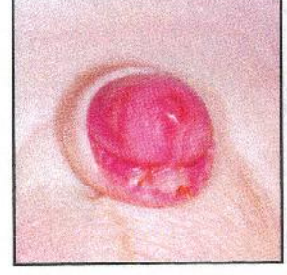Patient F



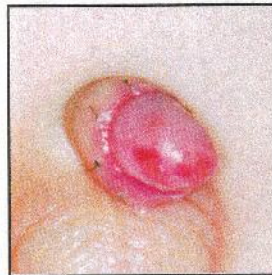Patient G



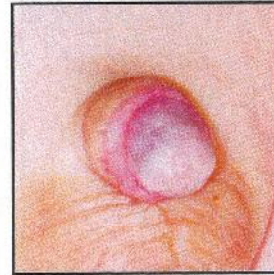Patient H



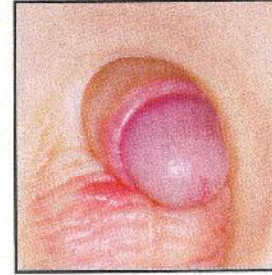
Patient I




Patient J



Patient K

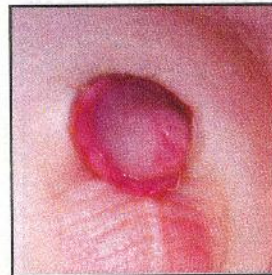


Patient L

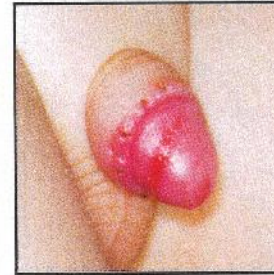

A bit of redness left after healing tissue comes off

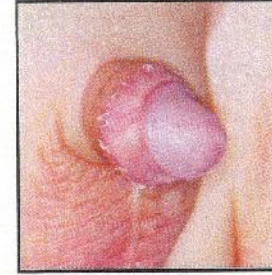Patient M



Patient N



Patient O



Patient P

