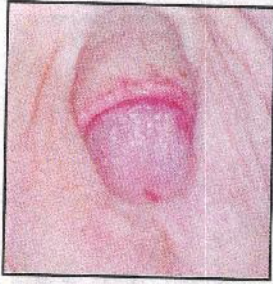

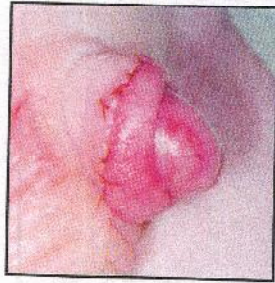
# DAY 7

The healing tissue begins to come off.

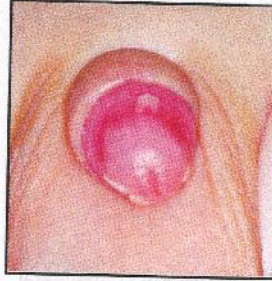Patient A



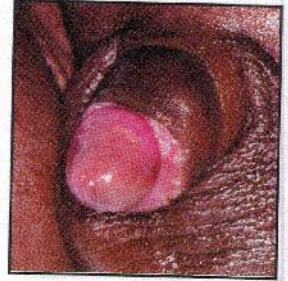Patient B



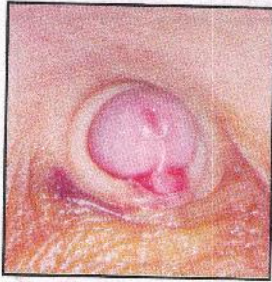Patient C



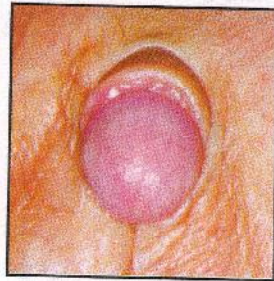Patient D



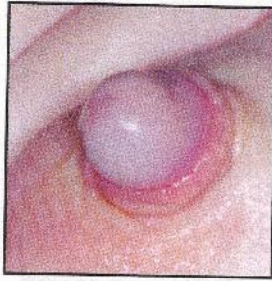Patient E



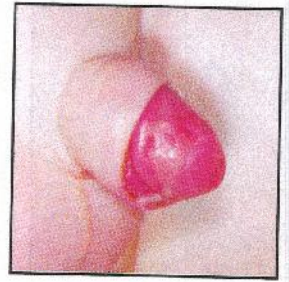Patient F



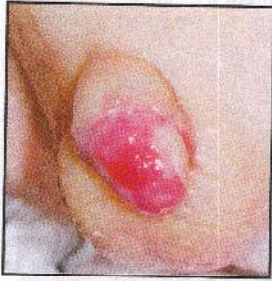Patient G



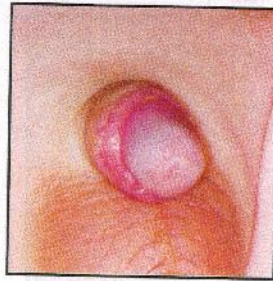Patient H



Patient I

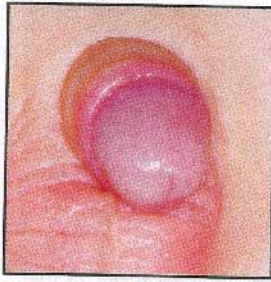

Patient J



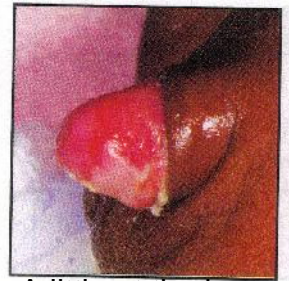The blue hue is normal

Patient K

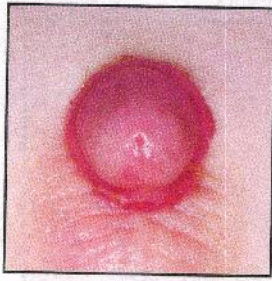

This redness is normal

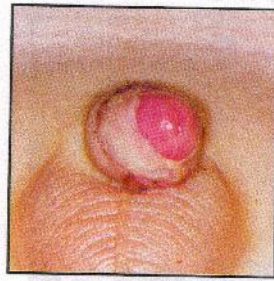Patient L



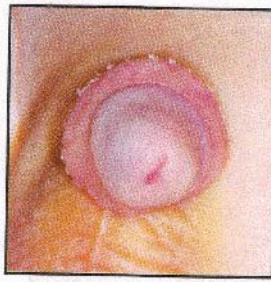Patient M



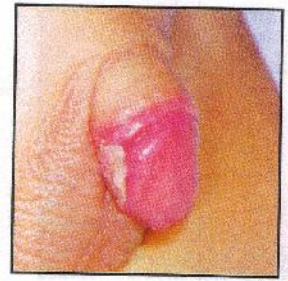Patient N



Patient O



Patient P



A little at the bottom

Still has it around the base of head of penis